

Microbial keratitis after corneal collagen crosslinking

Juan J. Pérez-Santonja, MD, Alberto Artola, MD, Jaime Javaloy, MD, Jorge L. Alió, MD, PhD,
José L. Abad, PhD

Several infiltrates appeared in the upper midperipheral cornea of a 29-year-old woman who had had uneventful corneal collagen crosslinking (CXL) with riboflavin and ultraviolet-A light (UVA) for the treatment of keratoconus in the right eye. *Staphylococcus epidermidis* keratitis was confirmed by microbiological studies, which guided treatment with topical fortified antibiotic agents. Before CXL, the best spectacle-corrected visual acuity (BSCVA) in the right eye was 20/25, the manifest refraction was $-0.25 -0.25 \times 125$, and the anterior segment was normal under biomicroscopy. Five months after the procedure, the BSCVA was 20/22, the manifest refraction was $+1.00 -2.50 \times 40$, and slitlamp examination revealed a mild residual haze in the upper midperipheral cornea. Collagen crosslinking with riboflavin-UVA is a minimally invasive method but traditionally requires epithelial removal, which could be a predisposing factor to bacterial keratitis.

J Cataract Refract Surg 2009; 35:1138–1140 © 2009 ASCRS and ESCRS

Keratoconus is a noninflammatory ectasia of the cornea that is usually bilateral. The condition typically starts at puberty, progressing in approximately 20% of cases to the extent that keratoplasty is necessary.¹

Hard contact lenses and corneal grafting have been the major treatment modalities for keratoconus, although some patients can now benefit from intracorneal ring segment implantation.^{1,2} None of these techniques treat the underlying cause of ectasia and, therefore, cannot stop the progression of keratoconus.³

In recent years, the technique of corneal collagen crosslinking (CXL) with riboflavin and ultraviolet-A

light (UVA) has been developed.³ This technique increases the corneal rigidity of treated corneas, and preliminary clinical studies have shown improvement and stabilization of keratectasia with few, if any, complications in patients with keratoconus.^{4,5}

We report a case of microbial keratitis that developed after CXL with riboflavin and UVA for the treatment of keratoconus. To our knowledge, this is the first report of microbial keratitis after CXL with riboflavin-UVA treatment.

CASE REPORT

A 29-year-old white woman was referred to the Cornea Section, Visum-Instituto Oftalmológico de Alicante, Alicante, Spain, in February 2008 for the correction of progressive keratoconus. The patient was unable to wear contact lenses; she did not have general health problems.

The best spectacle-corrected visual acuity (BSCVA) was 20/25 in the right eye and 20/32 in the left eye, and the manifest refraction was $-0.25 -0.25 \times 125$ and -1.00×120 , respectively. Biomicroscopy results of the anterior segment were normal for the right eye; light Vogt striae were observed in the left eye. Intraocular pressure was 12 mm Hg in each eye. Ophthalmoscopy revealed normal fundus in both eyes. Corneal thickness, measured with ultrasonic pachymetry (DGH-500 pachymeter, DGH Technology), was 450 μm and 430 μm in the right eye and left eye, respectively. Videokeratography showed a pattern consistent with keratoconus in both eyes (asymmetric bowtie with skewing of the radial axis above and below the horizontal meridian and inferonasal steepening).⁶ The videokeratography-derived indices keratometry (K) (central K-reading) and inferior-superior (I-S) dioptric asymmetry were 47 diopters (D) and 2.3 D, respectively, in the right eye and 51.2 D and the 4.1 D respectively, in the left

Submitted: October 9, 2008.

Final revision submitted: January 21, 2009.

Accepted: January 23, 2009.

From the Cornea and Refractive Surgery Section (Pérez-Santonja, Artola, Javaloy, Alió) and the Department of Microbiology (Abad), Visum-Instituto Oftalmológico de Alicante, and Miguel Hernández University School of Medicine, Alicante, Spain.

No author has a financial or proprietary interest in any material or method mentioned.

Supported in part by a grant from the Spanish Ministry of Health, Instituto Carlos III, Red Temática de Investigación Cooperativa en Salud "Patología ocular del envejecimiento, calidad visual y calidad de vida," Subproyecto de Calidad Visual (RD07/0062).

Corresponding author: Juan J. Pérez-Santonja, MD, Visum-Instituto de Oftalmológico de Alicante, Avenida de Denia s/n, Edificio Visum, 03016 Alicante, Spain. E-mail: jjpsantonja@coma.es.

eye. Based on these data, Krumeich stage 1 keratoconus was diagnosed in the right eye and Krumeich stage 2 keratoconus was diagnosed in the left eye.⁷ The patient was scheduled for CXL with riboflavin-UVA light in the right eye and intracorneal ring segment implantation in the left eye. The risks of the surgery were fully explained to the patient in accordance with the Declaration of Helsinki.

In March 2008, uneventful intracorneal ring segment implantation (Ferrara ring, Mediphacos) was performed in the left eye after a stromal tunnel was created with a femto-second laser (IntraLase Corp.). Three months after surgery, the uncorrected visual acuity (UCVA) was 20/20, the manifest refraction was -0.25×130 , and the cornea was clear and quiet under biomicroscopy.

In April 2008, the patient had CXL with riboflavin-UVA in the right eye. The surgical procedure was conducted under sterile techniques using topical anesthesia of oxybuprocaine 0.4%, 1 drop every 10 minutes twice before surgery. After the patient was placed under the operating microscope, an 8.5 mm circle was traced on the epithelium with a corneal marker and the epithelium within the circle removed with a blunt spatula. This was followed by instillation of 4 drops of a solution containing riboflavin 0.1% and dextran 20% (Ricrolin) for approximately 10 minutes. Penetration of the cornea and presence of riboflavin in the anterior chamber (riboflavin shielding) was monitored by slitlamp examination. After 2 to 4 additional drops of the riboflavin solution were instilled, the UV lamp was turned on to irradiate an 8.0 mm diameter of central cornea. Riboflavin 0.1% solution was applied every 5 minutes during the irradiation. The UV (wavelength 370 nm) source was a solid-state device consisting of 1 UV diode (Vega X linker, Compagnia Strumenti Oftalmici). The source was focused on the apex of the cornea at a distance of 50 mm to obtain a radiant energy of 3 mW/cm². The cornea was irradiated with the UVA diode for 30 minutes. After treatment, the eye surface was washed with 20 mL balanced salt solution, medicated with 2 drops of ciprofloxacin (Oftacilox) and 2 drops of cyclopentolate (Ciclopéjico), and dressed with a soft contact lens (Focus Night & Day, Ciba Vision). After the procedure, the patient was given paracetamol-codeine (500 mg/30 mg) every 8 hours for 2 days, cyclopentolate eyedrops 3 times a day for 2 days, and ciprofloxacin eyedrops 4 times a day for 5 days.

At the first follow-up visit, 2 days after surgery, the patient complained of photophobia and blurring in the right eye. Slitlamp examination revealed ciliary injection and 4 well-defined white nodules surrounded by small satellite lesions and hazy stromal infiltrate in the upper midperipheral cornea (Figure 1). Epithelial defects were present overlying the corneal infiltrates and in the central cornea due to epithelial repair. The anterior chamber reaction was mild. This picture was thought to represent microbial keratitis, and the immediate management involved scraping the corneal stromal infiltrates in the affected area with a spatula. The corneal samples were placed on a microscope slide for Gram staining; on blood, chocolate, and MacConkey agar and thioglycolate broth for bacterial culture; and on Sabouraud agar for fungal culture.

The smears revealed no microorganisms, but hourly topical fortified cefazolin (50 mg/mL) and topical fortified tobramycin (15 mg/mL) were started on the same day. Cultures were subsequently (after 48 hours of incubation) positive for *Staphylococcus epidermidis*. The organisms were identified based on their morphology, stain features, ability to produce catalase, inability to produce coagulase, and antibiotic susceptibility to novobiocin. Twenty-four hours after organism

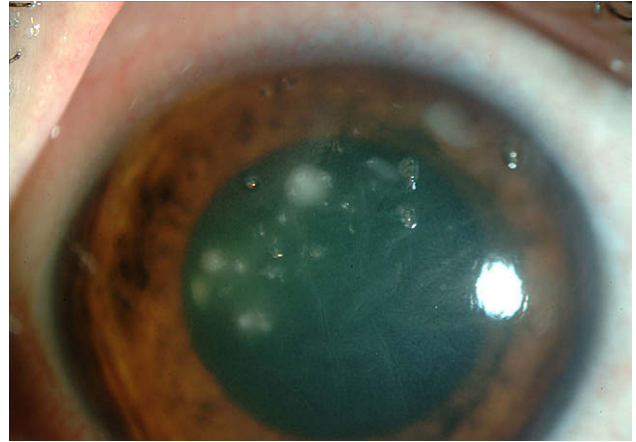


Figure 1. Right eye slitlamp photograph showing 4 well-defined, gray-white stromal infiltrates surrounded by small satellite lesions in the upper midperipheral cornea 4 days after CXL with riboflavin-UVA.

identification, an antibiotic-sensitivity test (Kirby-Bauer disk-diffusion method) showed that the isolated organism was sensitive to tobramycin/gentamicin, fluoroquinolones, and vancomycin but resistant to cefazolin. The treatment regimen was then changed to topical ofloxacin 0.3% (Exocin) and topical fortified tobramycin (15 mg/mL), which were given at 1-hour intervals around the clock for 2 days and decreased to 2-hour intervals for 5 days.

The patient's condition improved rapidly, with regression of the ocular inflammation and corneal infiltrates, and topical antibiotic agents were reduced to 4 times a day for 2 more weeks. One week after the antibiotic-sensitivity test, topical fluorometholone 0.10% (FML) 3 times a day was added to the antibiotic regimen. One month after CXL, an eye examination revealed moderate leucomas surrounded by stromal haze in the upper midperipheral cornea. Topical fluorometholone was continued twice a day for 1 additional month.

Five months after the treatment, the UCVA in the right eye was 20/32 and the BSCVA, 20/22. The postoperative refraction was $+1.00 -2.50 \times 40$. Slitlamp examination disclosed a mild haze in the upper midperipheral area (Figure 2), and the central corneal thickness was 405 μ m.

DISCUSSION

In contrast to other therapeutic measures for treating keratoconus, such as hard contact lenses, thermal keratoplasty, epikeratoplasty, or intracorneal rings, which are transient corrections,^{2,8,9} the new technique of CXL with riboflavin-UVA seems to be the first approach to stop or even reduce the progression of keratoconus.^{3,5} Preliminary clinical studies have shown long-term stabilization and improvement of keratoconus after CXL, with no vision-threatening complications.^{3,5} To our knowledge, no case of microbial keratitis related to CXL with riboflavin-UVA treatment has been reported.

In our case, the lesion appearance was suspected of being microbial keratitis, probably related to intraoperative or early postoperative contamination, and a proper microbiologic workup was undertaken.

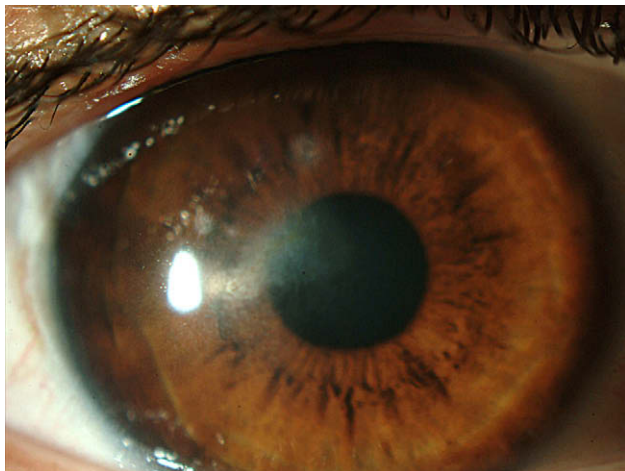


Figure 2. Slitlamp view of the right eye showing mild haze in the upper midperipheral cornea 5 months after treatment.

Collagen crosslinking with riboflavin-UVA is a minimally invasive method but traditionally requires epithelial removal for surgery and corneal stroma exposure for 30 minutes for irradiation; the epithelial defect usually takes from 2 to 5 days to heal completely. An intact corneal epithelium is an important defense barrier, and only a few bacteria, such as *Neisseria gonorrhoeae*, *Corynebacterium diphtheriae*, and *Listeria monocytogenes*, can penetrate an intact epithelium; most cannot. The compromised corneal epithelial integrity caused by CXL was probably the predisposing factor to bacterial keratitis in our patient, in the same way as corneal epithelial damage caused by contact lens wear, corneal trauma, or other corneal surgery procedures is a predisposing factor to microbial keratitis.^{10,11} It seems reasonable to postulate that the risk for infection might be lower in a transepithelial CXL technique,¹² since the epithelium remains intact, but more studies are necessary to confirm this statement.

Coagulase-negative staphylococci, including *S epidermidis*, are usually present in normal ocular flora, and more than 85% of eyelid cultures from the normal population are positive for coagulase-negative staphylococci.^{10,13} These microorganisms are very common etiologic agents of bacterial keratitis in the United States and Europe and usually cause opportunistic infection when the epithelium is compromised.^{10,14} With these data, we have enough information to identify *S epidermidis* as the causative organism isolated in our patient.

In our case, scraping the corneal infiltrates allowed us to obtain enough material for microbiologic processing and fast microbial identification that guided the proper treatment. We emphasize that the routine use of antibiotic agents after surgery was unable to prevent bacterial keratitis development in our patient.

This case illustrates the risk for microbial keratitis after CXL with riboflavin-UVA for the treatment of keratoconus. It represents our first microbial keratitis in a series of 18 CXL procedures, an incidence of 5.5%. The case also emphasizes the need for a surgical procedure conducted under sterile techniques, for postoperative surveillance, for the use of postoperative topical antibiotic agents, and for an informed consent for patients who elect this procedure for keratoconus treatment.

REFERENCES

1. Rabinowitz YS. Keratoconus. *Surv Ophthalmol* 1998; 42:297–319
2. Colin J, Velou S. Current surgical options for keratoconus. *J Cataract Refract Surg* 2003; 29:379–386
3. Wollensak G, Spoerl E, Seiler T. Riboflavin/ultraviolet-A-induced collagen crosslinking for the treatment of keratoconus. *Am J Ophthalmol* 2003; 135:620–627
4. Caporossi A, Baiocchi S, Mazzotta C, Traversi C, Caporossi T. Parasurgical therapy for keratoconus by riboflavin-ultraviolet type A rays induced cross-linking of corneal collagen; preliminary refractive results in an Italian study. *J Cataract Refract Surg* 2006; 32:837–845
5. Raiskup-Wolf F, Hoyer A, Spoerl E, Pillunat LE. Collagen crosslinking with riboflavin and ultraviolet-A light in keratoconus: long-term results. *J Cataract Refract Surg* 2008; 34:796–801
6. Rabinowitz YS, Rasheed K. KISA% index: a quantitative videokeratography algorithm embodying minimal topographic criteria for diagnosing keratoconus. *J Cataract Refract Surg* 1999; 25:1327–1335; errata 2000; 26:480
7. Krumeich JH, Daniel J, Knülle A. Live-epikeratophakia for keratoconus. *J Cataract Refract Surg* 1998; 24:456–463
8. Dana MR, Putz JL, Viana MAG, Sugar J, McMahon TT. Contact lens failure in keratoconus management. *Ophthalmology* 1992; 99:1187–1192
9. Sekundo W, Stevens JD. Surgical treatment of keratoconus at the turn of the 20th century. *J Refract Surg* 2001; 17:69–73
10. Huang AJW, Wichinsin P, Yang M-C. Bacterial keratitis. In: Krachmer JH, Mannis MJ, Holland EJ, eds. *Cornea*, 2nd ed. Philadelphia, PA, Elsevier Mosby Inc, 2005; 1005–1033
11. Pérez-Santonja JJ, Sakla HF, Abad JL, Zorraqino A, Esteban J, Alió J. Nocardial keratitis after laser in situ keratomileusis. *J Refract Surg* 1997; 13:314–317
12. Chan CC, Sharma M, Boxer Wachler BS. Effect of inferior-segment Intacs with and without C3-R on keratoconus. *J Cataract Refract Surg* 2007; 33:75–80
13. McCulley JP, Dougherty JM. Blepharitis associated with acne rosacea and seborrheic dermatitis. *Int Ophthalmol Clin* 1985; 25(1):159–172
14. Schaefer F, Bruttin O, Zografos L, Guex-Crosier Y. Bacterial keratitis: a prospective clinical and microbiological study. *Br J Ophthalmol* 2001; 85:842–847



First author:

Juan J. Pérez-Santonja, MD

*Vissum-Instituto Oftalmológico
de Alicante, Alicante, Spain*